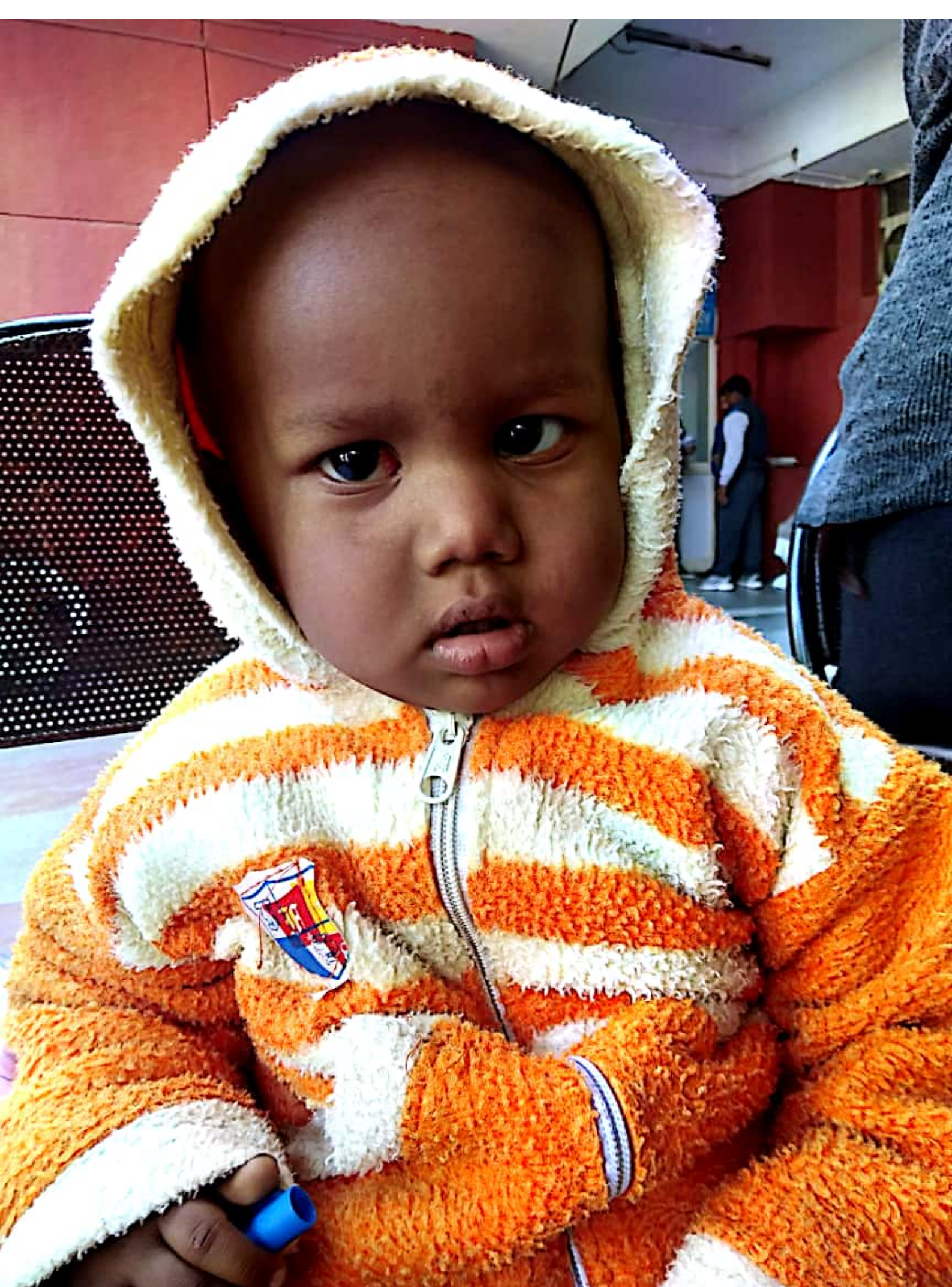





भारत सरकार

GOVERNMENT OF INDIA



लाल सिंह

Lal Singh

जन्म तिथि/DOB: 01/01/1985

पुरुष/ MALE

Mobile No: 9711342951

8614 1684 4709

VID : 9140 6328 5065 2450



आधार - आम आदमी का अधिकार



भारतीय विशिष्ट पहचान प्राधिकरण

UNIQUE IDENTIFICATION AUTHORITY OF INDIA

Download Date: 23/11/2015

पता:

S/O खचेरु लाल, बी-1/6, गली न-9, गौरव नगर-2 प्रेम
नगर-3, किरारी सुलेमान नगर, उत्तर पश्चिमी,
दिल्ली - 110086

Address :

S/O Khacheru Lal, B-1/6, Gali NO-9, Gaurav
Nagar-2 Prem Nagar-3, Kirari Suleman
Nagar, North West Delhi,
Delhi - 110086



Generation Date: 09/09/2018



1947
1800 300 1947

help@uidai.gov.in

www.uidai.gov.in

P.O. Box No. 1947,
Bengaluru-560 001

9.7 kg

उपचार/Treatment

BLR RB

Mentoux - positive

Gr C

Post 2 cycles → (32/118)

Gr D

No active complaint

Ulcer oral → Resolving

Dur (24/12)

RF - (N)

OT/PT - 62/43

TBB - 0.1

CBC → (N)

GA for 2N → Negative
Gene - post - negative

CXR → consolidation BL

UL & MZ

No effusion | Caution



अ० मा० आ० सं० अस्पताल / A.I.I.M.S. HOSPITAL
नहरिंग रोमी विभाग / Out Patient Department

शुद्धता के अन्तर् में धूम्रपान करना प्रतिषिद्ध है / SMOKING IS PROHIBITED IN HOSPITAL PREMISES

OPR-6

रोग/Unit _____

विध/Dept _____

opt. Paediatrics

OPD No. 20180220020169

P.D. Regn. No. _____

पता/Address _____

नाम/Name _____

पिता/पुत्र/दादा

F/S/W/II

उम्र/Age

पेशा/Profession

लिंग/Sex

हिड/ID No.

डिजिटल/Date

Barcode

रोग/Diagnosis

BIL AB

दिनांक/Date

उपचार/Treatment

32
9.9.18

L → G/D
R → G/C

last chemo 3/12/18

ECG shows signs of left
not chemotherapy.

slanting

→ response assessment
→ cont rephre

due for cycle 4
CBC
APT

D, Lij val 0.5mg
" carboplatin 190mg
" Etoposide 50mg


cont rephre

Lij Etoposide 50mg

N-18598

16-2-19
chemo 4th cycle
very CBC
APT

उपचार Treatment

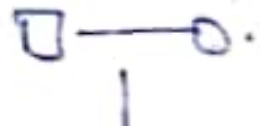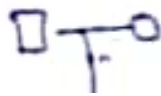
40. White reflex in  4-5-2 months

(R)

(L)

Leucocoria ⊕

Ret appears (N).



उपचार Treatment

C/S/B Dr Lomi in New RB clinic

Δ → BE @ IORB on USG & MRI

Dr F EUA for staging -

2.3 | 10/18
*NPO since 4am Tuesday
*OT 5th floor 9am

MRC →

2.2 | 10/18 - Monday.

R.No. - 53 10am

→ MRI reports. film & reports

ब. रो. वि. कार्ड
O.P.D. Card

दृष्टि



के अग्रिम अंश 1
के अग्रिम अंश 1

अनुभाग व दिन
Section and Day VI
बुधवार व शनिवार
Wednesday & Saturday

कमरा नंबर
Cabin No.

डा० राजेन्द्र प्रसाद नेत्र विज्ञान केन्द्र,
अ० आ० आयु० सं०, नई दिल्ली - ११००२९
Dr. Rajendra Prasad Centre for Ophthalmic Sciences
A.I.I.M.S., New Delhi-110029

यु एन आई डी संख्या
UHID No

104060426

आचार्य शशिका टंडन का एकक
Prof. Radhika Tandon's Unit

| रोगी का नाम Name of the patient | पुरु/पुत्री/पत्नी S/D/W | लिंग Sex | आयु Age | पता Address |
|------------------------------------|----------------------------|-------------|------------|----------------|
| PIYUSH | | M | 1 1/2 yr | |

| दिनांक DATE | निदान DIAGNOSIS |
|----------------|--------------------|
|----------------|--------------------|

उपचार Treatment

Date: 22/2/19

Case Seen/EVA done by Dr. LOMI / Dr. Ritika

Diagnosis: 1) Regressing GPC RB

2) Regressing Group D RB

No. of Cycles: 4 cycles (Last 27/0/19)

LAST EVA: 23/10/18

RE GPC RB.

LE TOTAL ROT GPC D RB.

LENS CLEAR & MASS

NO. GB INVOLVEMENT.



4.7
x 4.8

VITREOUS SEEDING

9
20/2/19

व० रो० वि० कार्ड

डा० राजेन्द्र प्र
अ० आ० आयु०
Dr. Rajendra Pri
A.I.I.M.S., New D
यु एच आई डी सं
UHID No.

DR. RAJENDRA PRASAD CENTRE FOR OPHTHALMIC SCIENCES

कमरा नंबर
Cabin No.

UHID: 100000426
Date No: 20180050126697
PIYUSH
S/O: LAL SINGH

17/02/2019
RPC OPD-DR. NEIWEJE
OMI
Unit VI
Room No.: 31
WED, SAT

ADDRESS: D-36 INDER ENCLAVE P-1 NANAK PUSHTA DELHI INDIA



रोगी का
Name of the

Sex Age Address

दिनांक
DATE

निदान
DIAGNOSIS

उपचार Treatment

27 FEB 2019

MRI brain & orbit

with contrast enhanced
and fat suppressed
in axial / coronal / sagittal

sections. 2 mm cuts passing
through optic nerve and
pituitary gland.

Keep report used / sat 9/2/19

115
(Answer)
kindly
help.

कृपया इस कार्ड को सुरक्षित रखें तथा अस्पताल में दिखाने के समय हर वक्त साथ लायें।

Kindly keep this Card safely and bring it on your follow-up visits.

- धूम्रपान निषेध
- कूड़ा कर्कट केवल कूड़ेदान में ही डालें
- शूकिये नहीं

① group D RB, ② group C RB.

उपचार/Treatment

4 cycles std CEV (last cycle 23/1/19).

EVA (22/2/19). ③ Regressing Gp C.

④ Regressing Gp D. (c subretinal calcification and subretinal seeds).

Planned for IV melphalan on Monday.

Inj VCR 0.5mg IV D1

Inj Carboplatin 173mg IV D1

Inj Etoposide 47mg IV D1, D2

0 Nasal discharge.
No H/O fever.

Med

On augmentin ⑤.
Chest Xray 19/2/19 - NAD.

Syp. Cetrizine 5mg/5ml 5ml to
Nasoclear drops 1° each instil
q 4 hourly

निदान
DIAGNOSIS

उपचार Treatment

(R) eye Residual vitreous seeds
after 3 cycles

Plan IV. Melphalan
on Monday & EVA

20mg/1ml

locks

My
Melphalan

Dr. Aparna
|
to take
Consent

हिरिंग रोगी विभाग / Out Patient Department

अस्पताल के अन्दर धूम्रपान करना है। / SMOKING IS PROHIBITED IN HOSPITAL PREMISES

OPR-6

रोगी/परीक्षण नं./O.P.D. Regn. No. _____

Dept Paediatrics

DEPT No 20180030028369

Clinic Name

CL No.

Room 7

Name PIYUSH PIYUSH

Male 1 Y

UHD 104060426 DT 28-11-2018



| लिंग Sex | वय Age | पता/Address |
|-------------|-----------|-------------|
| | | |

उपचार/Treatment

F/U/CP B/L RB

(R) group C.

(L) group D.

CE-MRI - No e/o
translesional / intra.
cranial
(LNAC review) No. ON contrast.

Received 1st cycle STD CEV on 30/10/18

cough / leucya x 2-3 days (Now improving)
No fever.

O/E - PR - 90/min
RR - 28/min
CFT < 3 sec.

No significant LAP

Chest - clear

CNS - S, S₂ (N)

?/A - left, No MSM

CNS - WNL.

Page 3

12
6/2/19

ब० रो० वि० कार्ड

रजि०

अनुभाग छ विन

DR. RAJENDRA PRASAD CENTRE FOR OPHTHALMOLOGICAL SCIENCES

UJID: 144888478
 Dept. No.: 20180050126697
 PIVUSH
 SODAL SINGH

Date: 06.03.2019
 RPC OPD DE NEWELL
 LUSHI
 Cabin VI
 Room No.: 32

UJID No. 20180050126697



VI
aturday

कमरा नंबर
Cabin No.

डा० राजेन्द्र प्रसाद
अ० भा० आयु०
Dr. Rajendra Prasad
A.I.I.M.S., New Delhi

यू एच आई डी रजि०
UHID No.

रोगी का
Name of the

Sex Age Address

दिनांक
DATE

निदान
DIAGNOSIS

उपचार Treatment

6/07 444 9 0 All Repeating IRR B

Total reced
Eggle of
chordings

① Querc

② Pecalatramb
amp D R B

Out for ② Excelsior
Admit in primary
Implant

C/DW
Dr Rachna Mehta

34A

DOA
09/03/19
#34A, 8:30AM

उपचार Treatment

EVA done & Unit 6 by Dr Loni

- (1) Group C RB
- (2) Total RD & Group D RB
 - Lens clear & ACES
 - NO Ciliary body involvement

